

Dynamic whole-spine MRI of contortionists

W.W. Orrison, Jr
T.G. Perkins

Touro University College of Osteopathic Medicine, Henderson, NV, USA.
Amigenics Inc., Las Vegas, NV, USA.
Spring Valley Nevada Imaging Center, Las Vegas, NV, USA.

Many athletic activities involve extreme spinal stress, but few involve such extreme forms of spinal mobility as that of circus contortionists. In this study, five female contortionists from a Mongolian circus school, between 20 and 49 years of age, were examined using a 3T cylindrical MR imaging system (Philips Achieva) to assess pathological changes that might be associated with the contortionists' act, in which the body is twisted into extreme positions.

Additional whole-spine dynamic images were obtained in two of contortionists using the Philips Panorama High Field Open (HFO) 1T open MR system (Figure 1) in order to define the range of motion achieved during extreme contortion.

Materials and methods

Whole-spine MR images were obtained in all five of the participants on a Philips Achieva 3.0T system, with participants in a supine position.

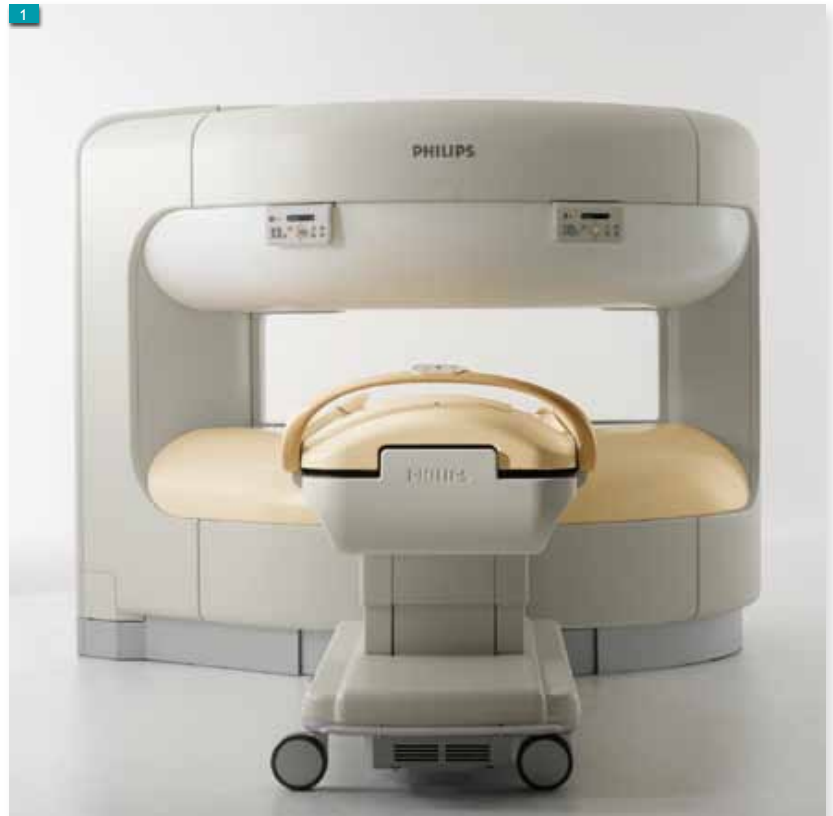Sagittal whole-spine images were acquired using a T2-weighted TSE sequence with TF 36, 270 mm FOV, 5 mm slice thickness, 234 x 304 imaging matrix, and TR/TE 3901/120.

Coronal whole-spine images were acquired with a similar sequence, with TR/TE 4682/120.

The images were acquired with three linked image stacks, and fused into a single image using the MR imaging system's software (Philips MobiView).

Transverse cervical spine images were acquired using a balanced FFE sequence with 210 mm FOV, 4.0 mm slice thickness, 280 x 224 matrix, and TR/TE 4.6/2.3. Transverse lumbar and thoracic spine images were obtained using a T2-weighted TSE sequence with TF 16, 220 mm FOV, 6 mm slice thickness, 202 x 256 matrix, and TR/ TE 2485/110.

In two of the five participants, whole-spine dynamic imaging was performed using the Philips



Panorama HFO system with the participant in a series of extreme contorted positions.

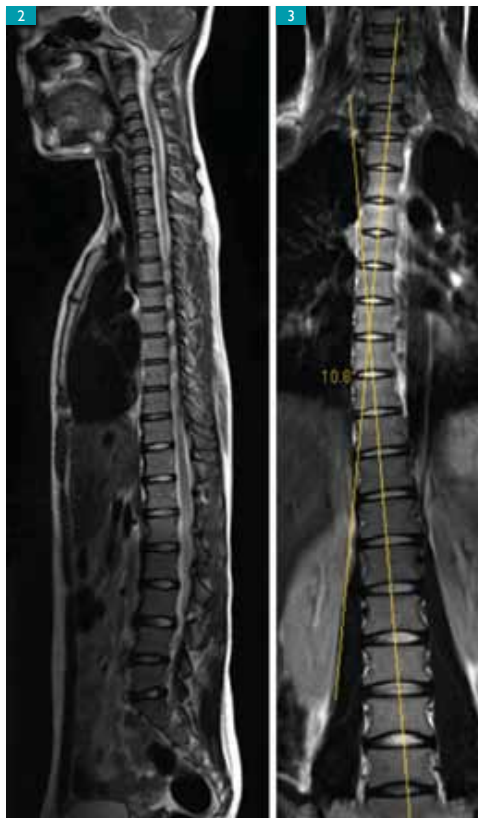▲ Figure 1. The Philips Panorama HFO 1T open MR system.

The Panorama HFO has a unique, integrated quadrature body coil, and provides access to a variety of patients who would otherwise be difficult or impossible to image with MRI. This not only includes patients with claustrophobia, but also patients who are unable to enter other MRI systems due to size, body habitus, or a requirement for unusual positioning such as the extreme examples of contortionists presented in this article.

The Panorama HFO's open access and wide, movable patient table made it possible to accommodate the contortionists during imaging in both the flexion and extension positions. The study would have been impossible to perform in a conventional cylindrical scanner.

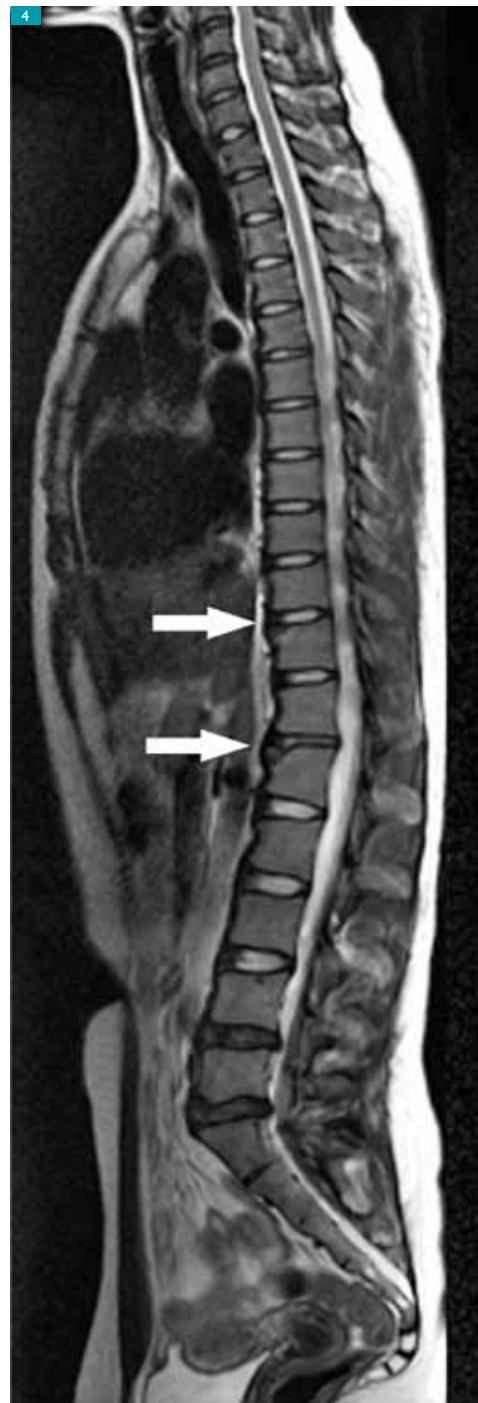
► **Whole-spine dynamic images were obtained in two contortionists.**

▶ Figure 2. 3.0T sagittal T2-TSE image showing lack of normal cervical and lumbar curvature.



▶ Figure 3. 3.0T coronal T2-TSE image showing mild dextroscoliosis.

▶▶ Figure 4. 3.0T sagittal 3.0T T2-TSE image showing anterior limbus fractures at T11 and L1 (arrows).



Whole-spine dynamic imaging

In this study, whole-spine MRI was very valuable in evaluating the spinal anatomy and pathological conditions of the participants. The dynamic real-time imaging during active contortion in the Panorama HFO provided a unique opportunity to demonstrate the severe stressors imposed by extreme extension of the spine. Advantages offered by the Panorama HFO's wide-open patient space include the ability to examine the entire spine in full motion through flexion and extension, improved resolution, and direct visualization of the spinal cord, intervertebral discs, and paraspinal soft tissues.

In the future, this method may also be used in other applications involving limited spinal motion and vertebral, disc or spinal cord displacement, such as pain management and traumatic spine injuries.

Image interpretation

Image interpretation was performed with evaluation of specific anatomical observations:

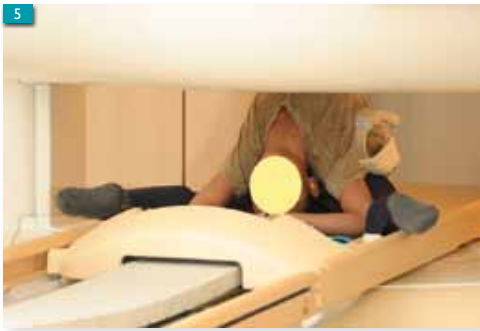- scoliosis
- straightening of normal cervical lordosis
- degenerative intervertebral discs
- annular tears
- disc bulges

- osteophytes
- anterosuperior limbus vertebrae fractures, defined as separation of the rim of the annular apophysis.

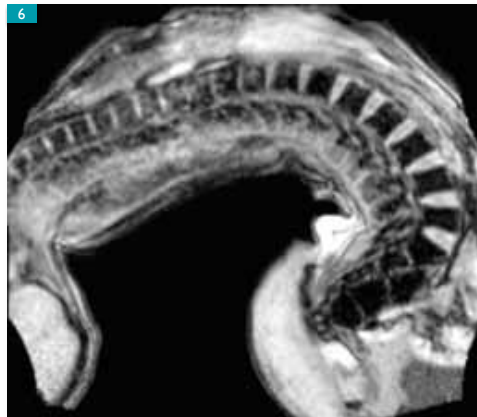Data analysis

Vertebral body angles were determined using a commercial DICOM viewing and analysis program (Philips DICOM Viewer, Philips Healthcare). The precision of the angle measurements was limited by the digital resolution of the images and the analysis program, resulting

▶ **The entire spine could be examined in full motion through flexion and extension.**



◀◀
Figure 5. Patient in the full extension position within the aperture of the Panorama HFO.



◀
Figure 6. Sagittal image from a high-speed dynamic series obtained with the Panorama HFO demonstrating full spinal extension. Images acquired using FFE, 400 mm FOV, 12 mm slice thickness, 128 x 256 matrix and TR/TE 7.3/3.7 with a 45° flip angle and a scan time of 0.96 sec per slice.

in an estimated precision of $\pm 2.5^\circ$ per vertebral body. Vertebral scoliosis angles were determined utilizing the Cobb angle method. Reformatting of images was performed using OsiriX.

Results

While the contortionists are comfortable in flexion positions (bending forward), they cannot maintain the extension positions (bending backward) for more than a few minutes.

Abnormalities that were found include anterior limbus fractures, in which a tiny segment of bone separates from the edge of the vertebral ring. The images showed that all five participants in this study had extremely straight spines in the sagittal plane, without the normal cervical and lumbar curvature (Figure 2). This could be of genetic origin, or could be the result of training from a very young age. In addition, all participants had a mild dextroscoliosis, presumably due to their training (Figure 3). Three of the five participants had anterosuperior limbus fractures at T-11 and the upper lumbar levels (Figure 4).

The 3T high-field MR images provided excellent detail of pathological changes including intervertebral disc degeneration. In the two participants who underwent dynamic whole-spine imaging using the Philips Panorama HFO system the regions of pathology corresponded to the areas of maximum angulation identified during extreme extension.

As might be expected, the most severe degenerative changes and complaints of back pain were associated with the older participants.

A total of three posterior cervical intervertebral disc bulges were identified in two of the contortionists, and lumbar disc bulges in three of the participants.

Thoracic anterior osteophyte formation was noted in two participants and lumbar anterior osteophyte formation with disc degeneration in two others.

A total of four anterosuperior limbus fractures were identified in three of the five participants: two limbus fractures (T-11 and L-1) in a 23-year-old individual (Figure 4), one limbus fracture (L-3) in a 22-year-old individual, and one limbus fracture (L5) in a 25-year-old individual.

Spinal range of motion

The spinal Range of Motion (ROM) was measured in the Panorama HFO system, which allowed the participants unrestricted freedom of movement from full extension to full flexion (Figures 5, 6). The ROM was remarkable, with a range of 238° from full extension (-188°) to full flexion ($+50^\circ$). Total vertebral extension was measured from the third cervical level (C-3) to the fifth lumbar level (L-5). The levels of greatest angulation were at the midcervical, thoracolumbar, and lower lumbar spine. The hip joints made the primary contribution to overall flexion, while extension positions involved greater segmental vertebral motion and contributed substantially to the entire ROM.

Discussion

To the best of our knowledge, this is the first medical imaging study to evaluate a group of contortionists and to report pathological findings associated with this activity. The most significant pathological findings, in our view, were the anterior limbus fractures.

A limbus fracture is a traumatic separation of a segment of bone from the endplate at the edge of the vertebral ring at the site of the attachment of the intervertebral disc. The fracture arises when the disc material herniates between the uncalcified peripheral ring apophysis of the endplates and the central cartilage. Because calcification and fusion of these elements generally occurs between 18 and 25 years of age, limbus fractures are most commonly encountered in adolescents and young adults.

► **The spinal range of motion was a remarkable 238° from full extension to full flexion.**

Much of the literature is concerned with posterior fractures [1], in which the protruding disc may compress neural tissues, but in the study reported here, all the fractures observed were of the anterior limbus.

Various classifications have been proposed. Epstein's [2] is the most comprehensive and, although it applies principally to posterior fractures, it does indicate the range of appearances of vertebral rim fractures. Type I fractures are simple avulsions of the cortex of the end plate, so thin that no obvious defect is present in the vertebral body although an arcuate fracture fragment is visible. Type II fractures are similar in position but include medullary bone and there is a defect in the vertebral body. Type III fractures are small and lateral. Type IV fractures run the full height of the vertebral body and extend to both vertebral endplates. All the fractures detected in our study would be classified as Type II.

The mechanism of limbus fractures is uncertain. They may result from a back injury, but in many cases, there is no trauma but a history of shearing and stress. The anterior limbus fractures encountered in these contortionists are likely related to hyperextension. One possibility is that when these contortionists hyperextend, the limbus fractures. There appears to be very little stress on the spinal column during flexion, with most of the flexion occurring at the hips (more than 180°) and with the contortionists able to hyperflex for long periods comfortably.

However, they can only maintain hyperextension for a few minutes and experience back pain when holding the hyperextended positions for a longer period. Thus, it appears that the major stress on the spine occurs during hyperextension in these remarkable individuals. Since this study, the troupe has altered its training regimen and other exercises to minimize these types of injuries.

The participants with limbus fractures described the initial onset of back pain as an episode of pain occurring during contortion activities. The onset and duration of the back pain, often lasting up to six months, may coincide with the vertebral pathology identified by MR imaging

but this cannot be confirmed because lumbar spine MR imaging studies predating the onset of symptoms were not available.

We hypothesize that the anterior limbus fractures represent traumatic avulsion fractures of the anterosuperior vertebral endplates related to extreme extension. This hypothesis, however, is based on a small sample size, given the limited number of practicing contortionists. Future research on a larger group of contortionists and investigations of their acute spinal injuries would help to confirm our assertion.

Conclusion

The dynamic images show the unusual degree of angulation of the spine during extreme extension and the remarkable increase in width of the anterior intervertebral disc space in this position as compared with the width in the flexion position. The availability of whole-spine dynamic MR imaging allows for diagnoses of conditions such as generalized or localized limitations in motion; abnormal vertebral, intervertebral disc, or spinal cord displacement; and as demonstrated here, unusual degrees of spinal mobility.

While this study was focused on a unique class of athletes, we believe the methods presented here can be applied to any patient experiencing a pathological condition of the spine that is not localized to one specific spinal region. Future research may open the use of whole-spine dynamic MR imaging into areas such as pain management and traumatic spinal injuries.

Acknowledgments

This article is based on a study carried out in cooperation with Randal R. Peoples, Janette W. Powell, Eric H. Hanson, Travis H. Snyder and Timothy L. Mueller, published in the *Journal of Neurosurgery: Spine* [3]. The author gratefully acknowledges the technical expertise provided by technicians Jon B. Gibson, Wendy Hopkins and Evelyn Robertson, and the contortion coach Angelique J. Talvat. The study was supported in part by a grant from Philips Healthcare ■

► **The anterior limbus fractures are likely related to hyperextension.**

► **These methods could be applied to any spinal pathology that is not limited to one specific region.**

References

- [1] Beggs I, Addison J. *Posterior Vertebral Rim Fractures*. *BJR*. 1998; 71: 567-572.
- [2] Epstein NE. *Lumbar Surgery for 56 Limbus Fractures*. *Spine*. 1992; 17(12): 1489-1496.
- [3] Peoples RR, Perkins TG, Powell JW, Hanson EH, Snyder TH, Mueller TL, Orrison WW. *Whole-Spine Dynamic Magnetic Resonance Study of Contortionists: Anatomy and Pathology*. *J Neurosurg Spine*. 2008; 8: 501-509.